



**PATIENT**

Atlas King

**PRESENTING CLINICAL SIGNS**

History: Recheck echo. On cardiac supplements because he is on a grain free diet for allergies. Pertinent previous echo findings (Vital Rads 3/2021): normal LA/LV, FS 29%, MR/TR/AI; B1

**SPECIES**

Canine

**ECHOCARDIOGRAM FINDINGS**

2D, m-mode, color flow and doppler imaging is available. Mild diffuse thickening of mitral valve leaflets with no prolapse into the left atrial lumen. Mild anterior-directed mitral regurgitation with mild left atrial dilation. Normal MR velocity. Normal LV diameter with adequate myocardial function. The tricuspid valve appears normal with trace tricuspid regurgitation. Normal right atrial and ventricular diameter and morphology indicating no overt evidence of pulmonary arterial hypertension. The pulmonic and aortic valves are normal in morphology and mobility. Normal pulmonic and aortic outflow velocities with laminar flow. Trace aortic and no pulmonic insufficiency. No pericardial or pleural effusion noted. No obvious cardiac masses. Sinus rhythm with isolated VPCs is noted throughout the study (single-lead ECG attached).

**BREED**

German Shepherd

**SEX**

Male

**AGE**

8 years

**CARDIAC CHART**

**WEIGHT**

104lbs

CANINE CARDIAC PARAMETERS	MR VMAX (m/s)	TR VMAX (m/s)	LA/AO (Boon method)	LA/AO (Heart Base; Swe)	FS (%)	EF (%)	EPSS (cm)
<b>NORMAL PARAMETER</b>	4.5-5.5	<2.7	1.3	<1.6	28-40	40-100	<0.6
<b>PATIENT</b>	5.0	NM	1.4	1.3	28	50	0.5
CANINE CARDIAC PARAMETERS	HR (BPM)	AV VMAX (m/s)	PV MAX (m/s)	BODY WEIGHT (kg)	LA 2D short axis Base view (cm)	LVIDd Avg; 2D and m-mode short axis (cm)	LVIDs Avg; 2D and m-mode short axis (cm)
<b>NORMAL PARAMETER</b>	50-100	0.7-1.7	0.7-1.6	BELOW	BELOW	BELOW	BELOW
<b>PATIENT</b>	80	1.4	0.7	47.2	3.7	4.9	3.5
*Normal chamber parameters expressed as a mean value (SD)				3	1.27 (5.3)	2.46 (2.46)	1.36 (5.5)
<b>BODY WEIGHT DEPENDENT PARAMETERS</b>				5	1.40 (4.5)	2.74 (5.2)	1.60 (4.7)
<i>*Note: All measurements based upon multi-modal images and methods. An average value is reported.</i>				10	1.50 (3.8)	3.27 (3.5)	2.06 (3.1)
				15	1.83 (2.0)	3.71 (2.4)	2.43 (2.1)
				20	2.02 (1.9)	4.14 (2.2)	2.80 (2.0)
				25	2.18 (2.4)	4.48 (2.9)	3.10 (2.5)
				30	2.33 (3.3)	4.83 (3.9)	3.39 (3.4)
				35	2.48 (4.3)	5.17 (5.0)	3.69 (4.5)
				40	2.62 (5.2)	5.48 (6.1)	3.96 (5.4)
				50	2.88 (7.1)	6.07 (8.3)	4.46 (7.4)

**INTERPRETED BY**

Maggie Machen Lamy, DVM, DACVIM (Cardiology)

**IMAGING PERFORMED BY**

Sands Hill Mobile Veterinary Ultrasound

**HOSPITAL NAME**

Surf City Animal Hospital

**REFERRING VET**

Dr.Wick

**INVOICE**

22916

**DATE**

3/3/22

**INTERPRETATION OF THE FINDINGS & FURTHER RECOMMENDATIONS**

Chronic degenerative valve disease causing mild mitral and trace tricuspid regurgitation without significant progression. Lack of significant left atrial enlargement indicates the current risk for complication is low. A small aortic leak is noted, and lifelong blood pressure monitoring is advised. The systolic function is adequate for this signalment (similar to 2021); however, given the diet, serial monitoring is certainly recommended. Finally, isolated VPCs are noted throughout the study and a **screening ECG is strongly recommended** as well. No additional issues are noted in this study.



## PATIENT

Atlas King

## SPECIES

Canine

## BREED

German Shepherd

## SEX

Male

## AGE

8 years

## WEIGHT

104lbs

## INTERPRETED BY

Maggie Machen Lamy,  
DVM, DACVIM  
(Cardiology)

## IMAGING PERFORMED BY

Sands Hill Mobile  
Veterinary Ultrasound

## HOSPITAL NAME

Surf City Animal  
Hospital

## REFERRING VET

Dr. Wick

## INVOICE

22916

## DATE

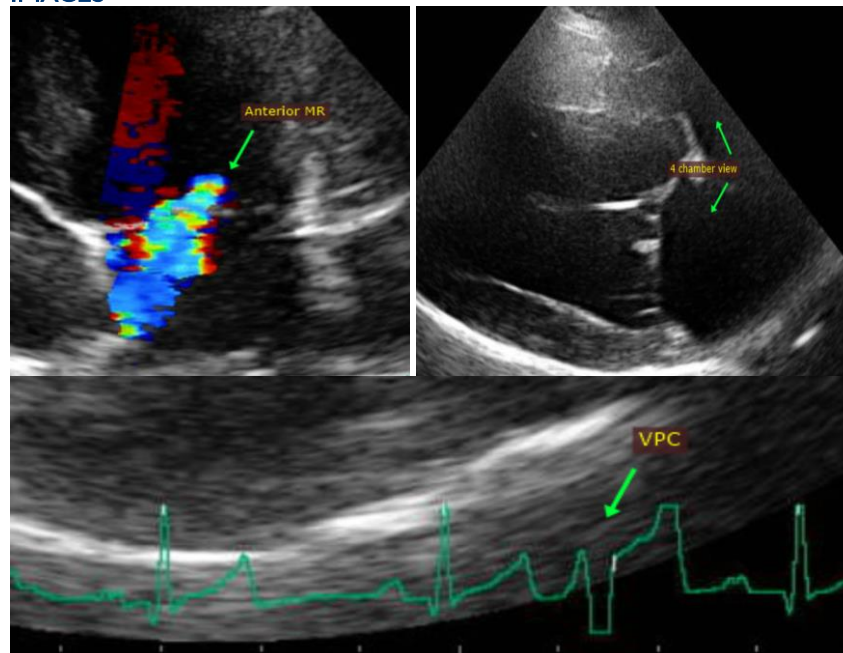
3/3/22

In a dog with no significant left atrial enlargement, no cardiac medications are clearly indicated. Assessment of progression in the future will help predict long term prognosis, which is highly variable at this stage (B1). Omega fatty acid supplementation and mild salt restriction may be of some long-term benefit. Monitor for development of a cough, labored breathing, exercise intolerance or collapse episodes.

From a structural standpoint, anesthetic risk is considered mild if needed. **This does not take into consideration the VPCs, which warrant further evaluation.** Cardiac protective drug choices (opioid/benzodiazepine premedication, propofol or alfaxalone induction, isoflurane gas) are recommended. Pre-oxygenate for 5-10 minutes prior to induction. Monitor for arrhythmias, hypotension, and hypoxia both intra and post-operatively and intervene as necessary. Mild IV fluid restriction is recommended to avoid fluid overload. Avoid heart rate stimulating drugs such as atropine unless clinically indicated.

Recommend conservative monitoring with a recheck echocardiogram in 6 months, sooner if any development of clinical signs.

## IMAGES



The information and recommendations provided are based on the images presented by the referring veterinarian. No evaluation can be communicated regarding pathology that was not visible in the image/video clips provided.

Thank you for this referral. This report was generated using transcription software, and minor dictation errors may be present. If the clinical or image interpretation does not parallel your findings or if I can be of any further assistance, please contact me.

Maggie Machen Lamy, DVM  
Diplomate of the American College of Veterinary Internal Medicine (Cardiology)



**PATIENT**

info@sonopath.com

Atlas King

**SPECIES**

Canine

**BREED**

German Shepherd

**SEX**

Male

**AGE**

8 years

**WEIGHT**

104lbs

**INTERPRETED BY**

Maggie Machen Lamy,  
DVM, DACVIM  
(Cardiology)

**IMAGING  
PERFORMED BY**

Sands Hill Mobile  
Veterinary Ultrasound

**HOSPITAL NAME**

Surf City Animal  
Hospital

**REFERRING VET**

Dr.Wick

**INVOICE**

22916

**DATE**

3/3/22